

## Fully Endoscopic Bilateral Cervical Laminotomy with Unilateral Approach for Cervical Spinal Stenosis and Myelopathy: A Case Series

Jian Shen\*

Department of Spine Surgery, Mohawk Valley Orthopedics, Center for Spine Regeneration Surgery, New York, USA

### Abstract

**Background:** Expansile laminoplasty or laminectomy is usually used to treat cervical myelopathy attributable to canal stenosis. However, detachment of the posterior cervical muscles is thought to contribute to postoperative axial neck pain and kyphosis, instrumented posterior fusion has to be done with laminectomy. Minimizing the amount of muscular dissection will reduce the likelihood of these complications and patients will have quicker recovery.

**Purpose:** To present a case series using fully endoscopic posterior cervical bilateral decompression technique with a unilateral approach to treat central canal stenosis and myelopathy.

**Materials and Methods:** Eighteen patients underwent fully endoscopic posterior cervical bilateral laminotomy/decompression with unilateral approach; 1-3 levels of posterior cervical bilateral decompression were accomplished. The preoperative and postoperative records of all the 18 patients were reviewed. Outcome was assessed by neurological status and modified JOA myelopathic scores (mJOA). Average follow-up was more than 18 months.

**Results and Discussion:** There was no complication related to the surgery in all 18 patients. Average operative time was 72 minutes/level. Muscle weakness and sensory deficit significantly improved in all patients. Gait improved in 15 patients. Analysis of the mJOA scores also showed statistically significant improvement.

**Conclusion:** Results from this case series shows that fully-endoscopic posterior cervical decompression for central stenosis is a safe and effective treatment for patients with cervical spinal stenosis and myelopathy.

**Keywords:** Fully endoscopic; Bilateral decompression; Unilateral approach; Cervical laminotomy; Cervical myelopathy

### Introduction

Surgical decompression via an anterior or posterior approach is the treatment of choice for patients with cervical spinal stenosis/cord compression and cervical myelopathy. Traditional open and tubular approaches for treatment of central and lateral recess spinal stenosis involve laminotomy or laminectomy with removal of overgrown ligamentum flavum and a portion of the medial facet joints in order to decompress the central canal and lateral recess. Posterior minimally invasive compression techniques allow preservation of motion segment and neural decompression without fusion. Microendoscopic laminotomy (MED) patients have significantly less postoperative axial pain and improved subaxial cervical lordosis when compared with traditional laminoplasty patients [1].

Fully-endoscopic posterior cervical laminectomy/laminotomy follows similar principle of MED but is a more minimally invasive approach with unique advantages. This case series describes a step-by-step technique for fully-endoscopic cervical laminectomy/laminotomy and its unique advantages to achieve bilateral decompression with unilateral approach for patients with significant central cervical stenosis and clinical myelopathy.

### Materials and Methods

#### Operative procedure

Under general anesthesia, patients underwent full endoscopic cervical laminotomy (bilateral decompression with unilateral approach), with the ILESSYS Delta endoscopic system (Joimax, Irvine, USA). This system has a 12.0-mm outer diameter, and 10.2-mm inner diameter canula, the endoscope has a 10-mm outer diameter and a 6-mm working channel, and a 15-degree viewing angle. Under endoscopic view, decompression could be achieved using the high-speed endoscopic drill. Straight micro-graspers were used to remove ligamentum flavum, and endoscopic Kerrison punches

(both 40-degree angle and 90-degree angle) with 1.5-mm footprints were used to remove additional bone and ligament (Figures 1A and 1B). Meticulous dissection of the interface between the ligamentum flavum and the dura was done with blunt-tipped micro nerve hook, with the help of continuous fluid irrigation. Any pressure/compression

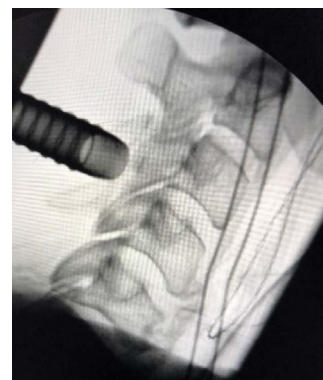

Figure 1A

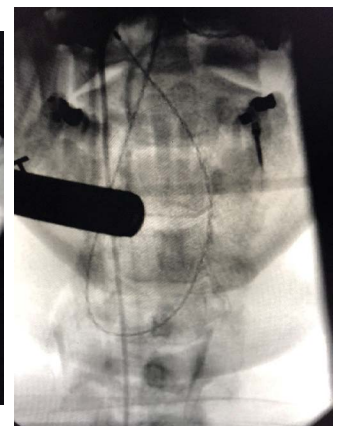


Figure 1B

**Figure 1: (A and B)** Intra-operative fluoroscopy images showing the cannula placement for C3/C4 level decompression.

\*Corresponding author: Jian Shen, Department of Spine Surgery, Mohawk Valley Orthopedics, Center for Spine Regeneration Surgery, 215 East 77th Street, New York-10075, USA, Tel: + 518842-2663, E-mail: [james2173@yahoo.com](mailto:james2173@yahoo.com)

Received July 22, 2018; Accepted August 08, 2018; Published August 13, 2018

**Citation:** Shen J (2018) Fully Endoscopic Bilateral Cervical Laminotomy with Unilateral Approach for Cervical Spinal Stenosis and Myelopathy: A Case Series. J Spine S7: 009.doi:10.4172/2165-7939.S7-009

**Copyright:** © 2018 Shen J. This is an open-access article distributed under the terms of the Creative Commons Attribution License, which permits unrestricted use, distribution, and reproduction in any medium, provided the original author and source are credited.

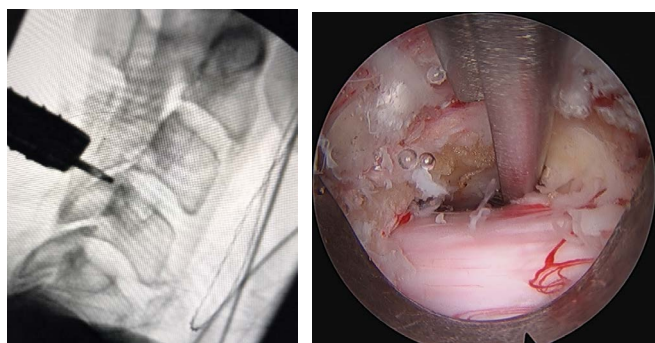


Figure 1C  
Figure 1D  
**Figure 1: (C and D)** Intra-operative fluoroscopy and endoscopic images showing contralateral decompression.

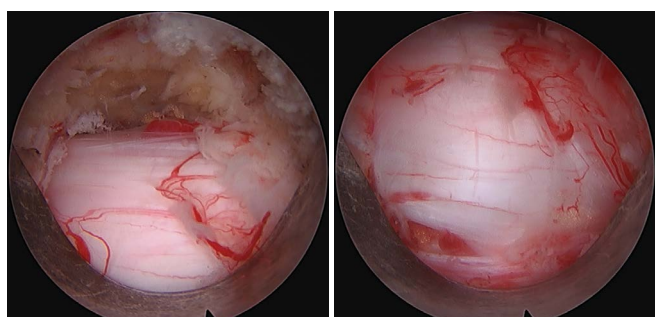


Figure 1E  
Figure 1F  
**Figure 1: (E and F)** Intra-operative endoscopic images showing contralateral and ipsilateral thecal sac after decompression.

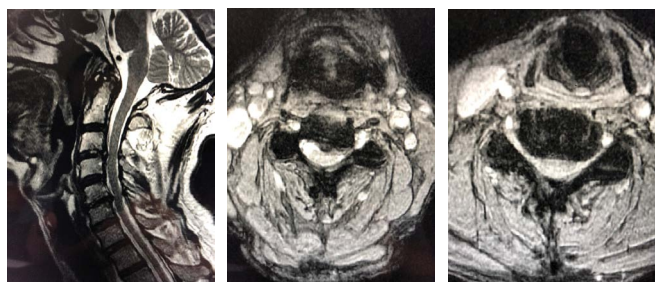


Figure 2A  
Figure 2B  
Figure 2C  
**Figure 2: (A)** Pre-operative MRI images of a 66-year-old male showing significant cord impingement at **(B)** C3/C4 **(C)** C5/C6.

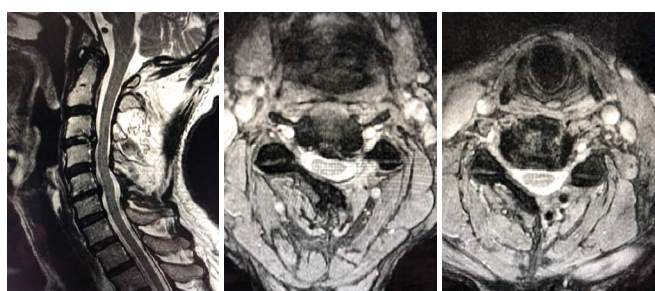


Figure 3A  
Figure 3B  
Figure 3C  
**Figure 3: (A)** MRI images of the same patient 24 months post-op, **(B)** C3/C4 **(C)** C5/C6.

on the spinal cord or nerve root was avoided throughout the surgery. Hemostasis was achieved with a radiofrequency probe. At the end of decompression, the thecal sac was seen well decompressed of both the contralateral and ipsilateral side, and nice pulsation of the spinal cord was seen (Figures 1C and 1D). The 12-mm incision was closed in layers with absorbable sutures without a drain. A separate incision was used for a different level and bilateral laminotomy/decompression was done in similar manner (Figures 1E and 1F).

## Results

In total, 18 patients were in this case series. Mean age was 68 years (range, 57-86 years). Mean preoperative mJOA score was 10.2. The mean operation time was 72 minutes/level, and blood loss was minimal. There was no intraoperative or postoperative complication, including cord or nerve root injury, C5 nerve palsy, dural tear/CSF leak, hematoma, or infection. Mean hospital stay was 0.7 day (range 0-1 day).

Mean follow-up was 18 months (range, 6-28 months). The mean postoperative mJOA score was 15.1, recovery rates 48%, showing statistically significant improvement ( $p < 0.001$ ). Clinically, muscle weakness and sensory deficit significantly improved in all patients. Gait improved in 15 patients. No patient showed neurologic deterioration after surgery.

## Discussion

Cervical spondylotic myelopathy, radiculopathy and myeloradiculopathy can be managed by lamino-foraminotomy, bilateral decompression using posterior approach for single or multilevel compression (Figures 2A, 2B and 2C). For both effectiveness and safety, there is no clear advantage to either an anterior surgical approach or a posterior surgical approach when treating patients with multilevel CSM [2,3]. However, Multi-level anterior cervical corpectomy carries an approximately 22% risk of surgical mortality and major morbidity including deep vein thrombosis, myocardial infarction, pneumonia and death, due to the long operating time and significant blood loss [4]. In addition, for patients with OPLL, surgical removal of the OPLL mass through an anterior approach is technically demanding and is associated with higher incidence of perioperative complications compared with posterior surgery [5]. Because of its even less invasiveness, better visualization and the continuous irrigation of fluid, fully-endoscopic approach has unique advantages for posterior decompression of the spinal canal (Figures 3A, 3B and 3C).

The evolution of surgical techniques to decompress the central canal and lateral recess has been from traditional open laminectomy, to microscopic, microendoscopic (MED), and fully-endoscopic techniques. The smallest tubular retractors used for MED surgery are 16-18 mm in diameter; the retractor used in this case is 12.0 mm in diameter. The working channel is more than 60% larger than that of the endoscope used in transforaminal surgery. The increased size of the working channel makes treating central spinal stenosis more feasible and efficient. The goal of fully endoscopic laminectomy/laminotomy is the same as open decompression, yet it preserves midline structures and facet function/stability. Other advantages include better visualization, much less bleeding, less need for narcotic pain medications, quicker recovery.

The disadvantages of fully-endoscopic laminectomy/laminotomy techniques described here include longer operative time, because it is a 'one-instrument-at-a-time' technique, only one instrument is used inside the working channel.

## Conclusion

Overall, endoscopic bilateral decompression of cervical spondylotic myelopathy with unilateral approach is a safe and an effective alternative treatment option in selected patients when pathologic changes are primarily posterior or multi-level anterior lesions with acceptable preoperative lordosis. However, this is a single surgeon case series, and the number of cases in the present study was relatively small. Therefore, long-term and more clinical and radiological data will be collected through continuous research, to further evaluate the safety and of this endoscopic procedure.

## References

1. Minamide A, Yoshida M, Simpson AK, Yamada H, Hashizume H, et al. (2017) Microendoscopic laminotomy versus conventional laminoplasty for cervical spondylotic myelopathy: A 5-year follow-up study. J Neurosurg Spine 27: 403-409.
2. Lawrence BD, Jacobs WB, Norvell DC, Hermsmeyer JT, Chapman JR, et al. (2013) Anterior versus posterior approach for treatment of cervical spondylotic myelopathy: A systematic review. Spine (Phila Pa 1976), 38: S173-S182.
3. Fehlings MG, Barry S, Kopjar B, Yoon ST, Arnold P, et al. (2013) Anterior versus posterior surgical approaches to treat cervical spondylotic myelopathy: outcomes of the prospective multicenter AOSpine North America CSM study in 264 patients. Spine (Phila Pa 1976) 38: 2247-2252.
4. Macdonald RL, Fehlings MG, Tator CH, Lozano A, Fleming JR, et al. (1997) Multilevel anterior cervical corpectomy and fibular allograft fusion for cervical myelopathy. J Neurosurg 86: 990-997.
5. Iwasaki M, Okuda S, Miyauchi A, Sakaura H, Mukai Y, et al. (2007) Surgical strategy for cervical myelopathy due to ossification of the posterior longitudinal ligament: Part 2: Advantages of anterior decompression and fusion over laminoplasty. Spine (Phila Pa 1976) 32: 654-660.

This article was originally published in a special issue, **Minimally Invasive Spine Surgery -II** handled by Editor(s). Dr. Anthony T.Yeung, Desert Institute for Spine Care, USA